

Highlights from the Italian National Congress of Imaging in Pulmonology 2025: fostering implementation of advanced technologies for precision patient-centered care

Guido Marchi¹, Michele Mondoni²

¹Pulmonology Unit, Cardiothoracic and Vascular Department, University Hospital of Pisa, Pisa, Italy; ²Respiratory Unit, ASST Santi Paolo e Carlo, Department of Health Sciences, Università degli Studi di Milano, Milan, Italy

ABSTRACT

The Italian National Congress of Imaging in Pulmonology, held in Milan on November 21st, provided a unique educational platform exploring the evolving role of thoracic imaging in respiratory medicine. Organized by the Italian Respiratory Society (SIP-IRS) Imaging Study Group, the congress brought together over 160 participants, including pulmonologists, radiologists, interventional specialists, and early-career professionals, reflecting the essential role of multidisciplinary collaboration in modern respiratory care. Topics included functional imaging approaches to small airway disease in COPD and asthma, multimodal imaging in lung transplantation, the role of CT angiography for haemoptysis management, and radiomics applications for quantifying emphysema patterns and fibrotic changes. The role of imaging in guiding inhaled and biological therapies was explored, alongside a lively debate on thoracic ultrasound for interstitial lung disease screening. Advanced sessions covered medical thoracoscopy techniques, quantitative ultrasound and artificial intelligence in pleural diseases, shape-sensing robotic-assisted bronchoscopy for peripheral nodules, expanding cryobiopsy applications, and imaging's role in monitoring progressive pulmonary fibrosis therapeutics. A distinctive feature was the first "Images in Pulmonology" contest, won by a remarkable case simultaneously depicting lung cancer and new life. This meeting report summarizes key congress highlights and underscores the importance of fostering multidisciplinary collaboration and structured imaging education to bridge the gap between technological capabilities and clinical expertise in respiratory medicine.

Key words: thoracic imaging, respiratory medicine, medical education, radiomics, artificial intelligence, robotics.

Correspondence: Guido Marchi, MD - Pulmonology Unit, Cardiothoracic and Vascular Department, University Hospital of Pisa, Via Paradisa 2, 56124, Pisa, Italy – E-mail: guido.marchi@ao-pisa.toscana.it

Conflict of interest: The authors declare that they have no conflicts of interest and received no funding. GM is member of the Editorial Board of *Multidisciplinary Respiratory Medicine*.

Acknowledgements: The authors thank the Italian Respiratory Society (SIP-IRS) for supporting this educational initiative, and all faculty members and participants for their valuable contributions to the success of the congress.

Introduction

Thoracic imaging has evolved from a purely diagnostic tool to an integrated component of respiratory practice, influencing detection, treatment monitoring, procedural guidance, and personalized care [1]. Yet despite this central role, advanced imaging competencies remain underrepresented in training curricula, creating a gap between technological capabilities and clinical expertise.

The Italian National Congress of Imaging in Pulmonology, held in Milan on November 21st, 2025, addressed this educational challenge while showcasing latest developments in respiratory imaging. Organized by the Italian Respiratory Society (SIP-IRS) Imaging Study Group, the congress brought together over 160 participants, including respiratory specialists, radiologists, interventional pulmonologists, and early-career professionals. This multidisciplinary composition reflected a core conviction: optimal respiratory care requires collaborative expertise spanning specialties.

While imaging technologies are advancing rapidly - from artificial intelligence (AI) to robotic-assisted procedures, from quantitative radiomics to point-of-care ultrasound - respiratory training may not always have kept pace. For example, recent surveys suggest that training opportunities and supervision for thoracic ultrasound (TUS) can sometimes be inconsistent across programs [2]. In certain contexts, this may limit imaging's full potential in personalized care, potentially contributing to suboptimal diagnostic pathways, delayed interventions, or missed therapeutic opportunities.

The scientific program provided comprehensive coverage across imaging's expanding scope. Topics included robotic bronchoscopy innovations, lung transplantation imaging evolution, haemoptysis radiological management, radiomics applications, functional small airway imaging, and thoracoscopic techniques. Particular focus addressed advanced TUS and AI in pleural diseases, cryobiopsy's expanding role, TUS evidence in interstitial lung diseases (ILD), and imaging biomarkers guiding therapy in obstructive diseases. The program also explored progressive pulmonary fibrosis perspectives, emphasizing imaging throughout the treatment journey.

The first "Images in Pulmonology" contest engaged participants - particularly early-career professionals - in case-based peer learning. Exceptional clinical cases, when thoughtfully presented, illustrate diagnostic challenges, demonstrate imaging-clinical reasoning integration, model structured presentation, and convey medicine's human dimension.

The following sections summarize key presentations and debates, organized thematically. Each synthesizes core content, highlights consensus and uncertainty, and identifies clinical and research implications. Collectively, these contributions illustrate contemporary respiratory imaging's breadth while underscoring multidisciplinary collaboration's critical importance in translating innovation into improved outcomes.

1. Small airways: the hidden frontier

Dr. Dejan Radovanovic, discussed by Prof. Stefano Centanni, presented functional imaging approaches to small airway disease - a pathobiological core of COPD and asthma [3]. These distal airways, measuring less than 2 mm in diameter, traditionally considered a silent zone, contribute substantially to airflow limitation and represent early intervention targets [4]. Advanced imaging modalities, including parametric response mapping and computational fluid dynamics, enable non-invasive visualization of small airway pathology, offering opportunities for early therapeutic intervention and disease progression monitoring [5-7].

Dr. Radovanovic emphasized that parametric response mapping derived from paired inspiratory-expiratory CT scans can quantify functional small airway disease, distinguishing it from emphysema and enabling COPD phenotyping with important therapeutic implications [8,9]. The discussion highlighted ongoing research correlating small airway imaging biomarkers with clinical outcomes and treatment responses [10]. The ability to visualize and quantify small airway disease before significant functional decline occurs represents a paradigm shift toward preventive interventions in obstructive lung diseases.

2. The imaging journey in lung transplantation

Prof. Paolo Solidoro, discussed by Prof. Michele Mondoni, traced imaging evolution in lung transplantation from candidate assessment through post-transplant surveillance [11–13]. Modern protocols integrate HRCT, magnetic resonance imaging, interventional pulmonology techniques and functional assessments to optimize donor-recipient matching, detect early complications such as primary graft dysfunction, and monitor chronic rejection, transforming transplant outcomes through earlier intervention [14,15].

The presentation emphasized that contemporary pre-transplant evaluation extends beyond simple size matching, incorporating a more comprehensive imaging-based assessment [16]. In this context, Prof. Solidoro highlighted how integrated imaging protocols have become an integral component of post-transplant management over the past decade, supporting longitudinal graft assessment within a structured and comprehensive follow-up framework, and informing clinical decision-making through the combined use of anatomical and functional information [17].

3. Haemoptysis: unraveling the bleeding source

Prof. Anna Rita Larici, discussed by Prof. Stefano Aliberti, addressed radiological strategies for managing haemoptysis [18,19]. CT angiography has become the gold standard for visualizing bronchial and non-bronchial arterial anatomy, identifying culprit vessels and predicting feasibility of endovascular treatment including bronchial artery embolization [19]. In massive bleeding, therapeutic aortography enables immediate haemostasis, exemplifying the integration of diagnostic and interventional imaging [19].

Prof. Larici systematically reviewed the anatomical complexity of bronchial arterial supply, including aberrant origins and systemic collaterals, emphasizing how CTA provides a crucial roadmap for interventional procedures [19,20]. The presentation addressed post-embolization follow-up strategies and management of recurrent bleeding, which occurs in 10–30% of cases [21,22]. The discussion emphasized that optimal haemoptysis management requires close collaboration

among pulmonologists, radiologists, and interventional radiologists within multidisciplinary teams.

4. Radiomics in respiratory diseases: quantifying the invisible

Prof. Mariaelena Occhipinti, discussed by Prof. Laura Carrozzi, explored radiomics' transformative potential in respiratory medicine [23]. Radiomics involves extracting quantitative features from medical images to enhance diagnostic and prognostic accuracy [24]. In lung cancer, texture analysis stratifies tumour aggressiveness and predicts treatment response [25]; in COPD, it quantifies emphysema patterns and vascular remodelling [26]; in interstitial lung disease, automated approaches facilitate detection of fibrotic patterns [27]. AI algorithms support radiological interpretation by reducing interobserver variability and enabling personalized risk stratification [28,29]. Rigorous clinical validation and standardization remain crucial before routine implementation [30].

The presentation emphasized that radiomics transforms subjective visual assessment into objective, reproducible quantitative data, potentially enabling earlier disease detection and more precise treatment monitoring. Prof. Occhipinti highlighted the need for standardized acquisition protocols and analysis pipelines to ensure reproducibility across centers and facilitate regulatory approval for clinical use. Despite the promise of radiomics, Prof. Carrozzi noted that integration into clinical workflows will require not only technical validation but also demonstration of improved patient outcomes and cost-effectiveness.

5. Inhaled and biological therapies: imaging the impact

Dr. Francesco Menzella, discussed by Prof. Fabiano Di Marco, and Dr. Dejan Radovanovic, discussed by Prof. Paolo Solidoro, presented the current state of obstructive airway disease management [31,32]. In COPD, treatment strategies are increasingly informed by phenotypic characterization, with HRCT contributing to the differentiation between

emphysema-predominant and airway-predominant patterns [33]. In severe asthma, imaging features such as airway wall thickness and mucus plugging have been explored as potential biomarkers in the context of biological therapies, an area of rapidly evolving pharmacological development in obstructive lung diseases [34–36]. Longitudinal imaging may support treatment monitoring and contribute to a more individualized therapeutic approach.

The presentations highlighted how imaging phenotyping enables precision medicine approaches in diseases traditionally treated empirically. The speakers discussed emerging imaging biomarkers under investigation that could enhance therapeutic selection and monitoring. Combining these biomarkers with clinical and molecular data represents the next step toward truly personalized management of obstructive airway diseases.

6. Thoracic ultrasound in interstitial lung disease: debating the evidence

A debate between Dr. Giosuè Catapano (supporting) and Prof. Riccardo Inchingolo (cautioning), moderated by Prof. Francesco Pistelli, examined TUS for ILD screening [37].

Dr. Catapano highlighted diagnostic accuracy evidence supporting TUS for early detection. In systemic sclerosis and rheumatoid arthritis, findings of ≥ 3 B-lines in two adjacent sites or >5 total B-lines strongly associate with ILD presence [38]. The 14-zone protocol (ERS/EFSUMB approach) enhances reproducibility. TUS offers radiation-free bedside monitoring for connective tissue diseases [39].

Prof. Inchingolo emphasized critical limitations: non-specificity, operator dependence, lack of standardized protocols, unstandardized cut-off values, and minimal evidence beyond autoimmune-related ILD. The European Respiratory Society statement recommended research but stopped short of endorsing routine clinical use [40].

Overall, TUS was framed as a potentially complementary screening approach in carefully selected clinical contexts, with its role still largely confined to research settings. The debate allowed attendees to

critically appraise both the methodological promise and the current limitations of the technique, reinforcing the importance of balanced interpretation of emerging evidence and cautious integration into clinical practice.

7. Thoroscopic examination: practical techniques and tricks

Dr. Gian Pietro Marchetti, discussed by Prof. Federico Mei, delivered a practical session on medical thoracoscopy's role in respiratory medicine [41]. Dr. Marchetti demonstrated systematic approaches including optimal port positioning, comprehensive inspection protocols, recognition of subtle malignancy indicators, and targeted biopsy strategies [42]. The session emphasized combining visual inspection with strategic biopsy planning to differentiate benign from malignant pleural involvement, reflecting thoracoscopy's growing integration and value in improving diagnostic yield while enabling therapeutic interventions such as pleurodesis [42].

Dr. Marchetti shared practical “tricks” developed through extensive clinical experience, including techniques for navigating adhesions, optimizing visualization in loculated spaces, and maximizing biopsy adequacy. The session highlighted the evolving role of medical thoracoscopy in contemporary pulmonology practice. Alongside the expansion of interventional competencies among pulmonologists, structured training in medical thoracoscopy is increasingly considered a relevant component of respiratory fellowship curricula [43].

8. Advanced imaging and artificial intelligence in pleural diseases

Dr. Guido Marchi, discussed by Prof. Donato Lacedonia, reviewed emerging and investigational applications of advanced imaging techniques and AI in pleural disease, building on recent work published by the SIP-IRS Imaging Study Group [44–47]. Exploratory quantitative ultrasound approaches were presented, including pixel-based density analysis for the assessment of non-expandable lung and the characterization of pleural effusions [48–50].

Additional techniques under investigation include color Doppler evaluation of intercostal vessels to support procedural safety [51,52], elastography in the setting of ultrasound-guided pleural biopsy [53], and contrast-enhanced ultrasound to assist lesion targeting [54]. The growing availability of handheld portable devices was also noted as a potential facilitator of point-of-care assessment across a wider range of clinical settings [55].

AI applications in this field were described as an area of active and rapid development [56]. Current research explores predictive algorithms for automated artifact detection, effusion segmentation, and pneumothorax identification, as well as generative approaches aimed at augmenting training datasets [47,57–60]. Collectively, these developments were discussed within the conceptual framework of an emerging data-driven approach to clinical imaging, while acknowledging that clinical utility remains to be established.

The presentation underscored that, despite encouraging preliminary findings, substantial methodological validation and standardization are required before routine clinical implementation [47]. Dr. Marchi emphasized the need for critical appraisal of AI-generated outputs and the continued central role of physician oversight, cautioning against premature or uncritical adoption of algorithmic tools [61–63].

9. Robotic bronchoscopy in interventional pulmonology

Dr. Piero Candoli, discussed by Prof. Lorenzo Corbetta, presented the state of the art of robotic bronchoscopy for peripheral pulmonary nodules [64–66]. Shape-sensing robotic-assisted bronchoscopy (SS-RAB) represents sophisticated technology for minimally invasive nodule diagnosis, offering precise navigation and stable sampling. Performance improves with cone-beam CT guidance [67]. However, costs remain high with absence of specific reimbursement and lack of cost-benefit data [68].

Dr. Candoli advocated for a “reasoned approach”: not replacing established methods in high-yield scenarios, but expanding diagnostic capacity in “difficult” scenarios where conventional techniques have limitations. This emphasizes robotic bronchoscopy’s

complementary role while acknowledging economic considerations and appropriate patient selection. Prof. Corbetta’s discussion highlighted the need for robust training programs and credentialing standards as this technology becomes more widely available [69]. The presentation concluded with the observation that technological sophistication must be balanced against clinical utility and economic sustainability in health-care systems with finite resources.

10. The expanding role of cryobiopsy

Prof. Sara Tomassetti, discussed by Dr. Paolo Carlucci, outlined transbronchial cryobiopsy’s applications beyond ILD diagnosis [70–72]. This technique now extends to endobronchial lesions, peripheral nodules, mediastinal lymph adenopathies and therapeutic applications, such as blood clots removal and ablation of central, endobronchial lesions [73]. As a diagnostic tool, cryobiopsy provides larger, better-preserved specimens than forceps and needles, with reduced crush artifact, improving histopathological interpretation [74].

The technique has transformed from a specialized ILD tool to a versatile sampling method with expanding indications, though standardized protocols remain under development. Prof. Tomassetti emphasized the importance of appropriate training and case selection to optimize safety and diagnostic yield, noting that complications, while uncommon, can be significant and require immediate recognition and management.

11. Future perspectives in progressive pulmonary fibrosis

Prof. Fabrizio Luppi, discussed by Prof. Michele Mondoni, traced therapy evolution for idiopathic pulmonary fibrosis (IPF) and progressive pulmonary fibrosis (PPF) [75,76]. Antifibrotic agents have altered the therapeutic landscape of IPF, shifting it from a uniformly progressive disease, with evidence indicating a potential to attenuate the rate of disease progression [77]. The lecture reviewed breakthrough trials establishing pirfenidone and nintedanib and expanding recognition of progressive fibrosing phenotypes beyond IPF [78].

Prof. Luppi highlighted promising investigational therapies including novel antifibrotic compounds, anti-inflammatory strategies, and combination approaches [79]. Imaging plays a crucial role throughout the therapeutic journey - from diagnosis and phenotyping to treatment monitoring and progression detection - enabling individualized management strategies. The presentation emphasized that while antifibrotics represent major progress, substantial unmet needs remain, particularly regarding prediction of which patients will develop progressive disease and optimal timing for treatment initiation. Quantitative imaging analysis may ultimately provide the predictive biomarkers needed to identify patients who will benefit most from early aggressive intervention.

12. “Images in Pulmonology”: the first national contest

A distinctive congress feature was the first national imaging contest engaging pulmonologists in educational case presentations. A scientific jury blindly evaluated anonymous submissions based on four parameters (each scored 1-5 points):

- **Technical image quality:** capacity to optimally represent anatomical structures relevant to the demonstrated pathology.
- **Clinical impact:** ability to provide useful clinical information representative of the pathological condition.
- **Originality and innovation:** distinctive case features including rarity of findings, presentation uniqueness, and innovative acquisition techniques.
- **Scientific relevance:** image contribution to diagnostic, educational, or research knowledge.

The winning presentation, “The Two Growths” by Dr. Liluta Minni (University of Brescia), featured a CT image simultaneously capturing ALK-positive lung adenocarcinoma with pleural metastases and a healthy fetus at 32 weeks’ gestation - two forms of cellular growth representing life’s profound contrasts (see

Figure 1). The patient delivered a healthy baby and, three years later, continues thriving on targeted therapy.

This extraordinary case illustrates how imaging captures the intersection of advanced diagnostics, molecular medicine, and human resilience, exemplifying the contest’s mission: exceptional presentations combining technical excellence with profound

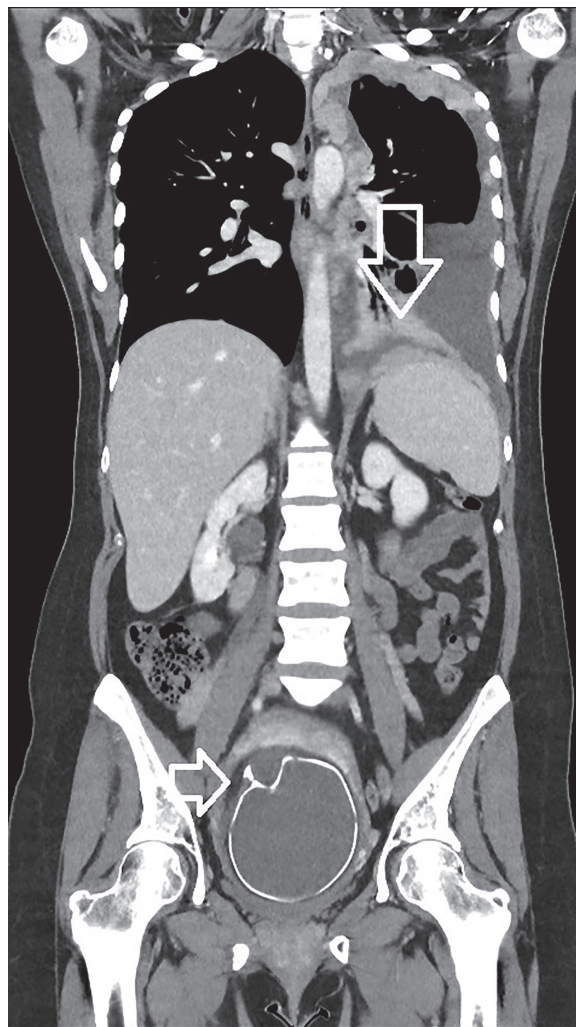


Figure 1. “The Two Growths” - Winning case of the first “Images in Pulmonology” contest. Coronal contrast-enhanced chest-abdomen CT scan demonstrating ALK-positive lung adenocarcinoma with pleural metastases in the left hemithorax (upper arrow) and a healthy fetus at 32 weeks’ gestation in utero (lower arrow). This remarkable image simultaneously captures two contrasting forms of cellular growth: malignant proliferation and new life. The patient successfully delivered a healthy baby and remains on targeted therapy with excellent disease control three years later, exemplifying the transformative potential of precision oncology in complex clinical scenarios.

clinical narratives inspire clinicians while advancing understanding of complex disease management. The case powerfully demonstrated imaging's capacity not merely to detect disease but to document human stories of hope and the life-affirming potential of precision medicine even in challenging circumstances.

13. Educational implications

The congress highlighted a critical paradox: while imaging has become transversal to modern practice, many pulmonologists complete training with limited competency in advanced imaging interpretation, procedural guidance, and emerging technologies. This gap threatens to limit imaging's potential in personalized respiratory care.

The congress format offered an educational blueprint worth replicating. By bringing together pulmonologists, radiologists, and interventional specialists, it fostered the multidisciplinary perspective essential for modern image-guided medicine. The imaging contest exemplified effective educational design, engaging early career professionals in presenting complex cases combining technical excellence with clinical reasoning.

Future educational initiatives should prioritize structured imaging curricula integrated throughout training programs, practical workshops in point-of-care ultrasound and image-guided procedures, multidisciplinary case-based learning, exposure to emerging technologies including AI and quantitative imaging, and development of critical appraisal skills - preparing clinicians to be protagonists in the evolving landscape of image-guided respiratory medicine.

Discussion

The Italian National Congress of Imaging in Pulmonology highlighted the increasingly transversal role of thoracic imaging in respiratory medicine, encompassing detection, monitoring, procedural guidance, and personalized care. Presentations illustrated a broad spectrum of innovations, from functional imaging of small airways and AI-assisted radiomics to robotic bronchoscopy and quantitative ultrasound in

pleural diseases. The congress emphasized the importance of integrating technological advances with clinical wisdom, balancing enthusiasm for innovation with considerations of validation, cost-effectiveness, and appropriate patient selection.

Multidisciplinary engagement proved central to the congress's success. Pulmonologists, radiologists, and interventional specialists shared insights shaped by their distinct expertise, while early-career professionals contributed through case presentations and the inaugural "Images in Pulmonology" contest. This collaborative environment underscored the value of peer-to-peer learning, structured debates, and hands-on demonstrations in advancing both knowledge and practical skills.

Several key themes emerged as priorities for respiratory imaging's coming decade: AI integration into clinical workflows, with attention to both potential and limitations; interventional pulmonology expansion through advanced guidance technologies; imaging biomarker development for precision phenotyping and treatment selection; diagnostic capability democratization through point-of-care technologies; and educational evolution paralleling technological advancement. Structured imaging curricula, supervised hands-on training, and cultivation of critical appraisal skills were highlighted as essential to ensure clinicians can translate these innovations into meaningful, patient-centered outcomes.

Conclusion

The congress highlighted that respiratory medicine's future is inextricably linked to imaging advancement. Realizing this potential requires not only continued technological innovation but also parallel development in training, clinical governance, and multidisciplinary collaboration. Educational initiatives must ensure clinicians are equipped to critically appraise new tools, apply them safely, and integrate them effectively into patient care pathways.

By fostering thoughtful innovation, rigorous validation, and comprehensive education, the Italian respiratory community is well-positioned to leverage imaging's full potential to enhance diagnostic accuracy, guide therapy, and ultimately improve patient outcomes and quality of life.

The congress model demonstrates a replicable framework for translating emerging technologies into clinical practice responsibly and sustainably, ensuring that innovation aligns with both patient-centered care and long-term professional competency.

References

- Nishino M, Schiebler ML. Advances in Thoracic Imaging: Key Developments in the Past Decade and Future Directions. *Radiology* 2023;306(2):e222536.
- De Boer WS, Veldman C, Parlevliet KL, Van Geffen WH, Edens MA, Stigt JA, et al. The current state of ultrasound training in pulmonary residency programmes in the Netherlands: an educational review. *Breathe* 2025;21(3):250099.
- Makimoto K, Singh GV, Kirby M. Advances in detecting small airway disease with medical imaging. *Eur Respir J* 2025;65(4):2500212.
- Lazarinis N, Fouka E, Linden A, Bossios A. Small airways disease in chronic obstructive pulmonary disease. *Expert Review of Respiratory Medicine* 2024;18(7):539–52.
- Kim T, Kim Y, Bak SH, Shin SH, Lee HY, Im Y, et al. Longitudinal parametric response mapping on CT in assessing functional small airway disease and emphysema in COPD. *Sci Rep* 2025;15(1):37221.
- Vasilescu DM, Martinez FJ, Marchetti N, Galbán CJ, Hatt C, Meldrum CA, et al. Noninvasive Imaging Biomarker Identifies Small Airway Damage in Severe Chronic Obstructive Pulmonary Disease. *Am J Respir Crit Care Med* 2019;200(5):575–81.
- Mohamady YK, Geudens V, De Fays C, Zapata M, Hagrass O, Aversa L, et al. Computational fluid dynamics of small airway disease in chronic obstructive pulmonary disease. *EBioMedicine* 2025;114:105670.
- Galbán CJ, Han MK, Boes JL, Chughtai KA, Meyer CR, Johnson TD, et al. Computed tomography-based biomarker provides unique signature for diagnosis of COPD phenotypes and disease progression. *Nat Med* 2012;18(11):1711–5.
- Pompe E, Galbán CJ, Ross BD, Koenderman L, Ten Hacken NH, Postma DS, et al. Parametric response mapping on chest computed tomography associates with clinical and functional parameters in chronic obstructive pulmonary disease. *Respir Med* 2017;123:48–55.
- Chukowry PS, Spittle DA, Turner AM. Small Airways Disease, Biomarkers and COPD: Where are We? *Int J Chron Obstruct Pulmon Dis* 2021;16:351–65.
- Calvert AD, Hazelton TR. Role of imaging in lung transplantation evaluation. *J Thorac Dis* 2020;12(9):5147–58.
- Kim SJ, Azour L, Hutchinson BD, Shirsat H, Zhou F, Narula N, et al. Imaging Course of Lung Transplantation: From Patient Selection to Postoperative Complications. *RadioGraphics* 2021;41(4):1043–63.
- LiNgY, PaulN, PatsiosD, WalshamA, ChungTB, KeshavjeeS, et al. Imaging of Lung Transplantation: Review. *American Journal of Roentgenology* 2009;192(3_supplement):S1–13.
- Thomas C, Williams M, Shlobin OA. Lung Transplantation: Selection of Candidates. *OBM Transplant* 2023;07(04):1–33.
- Sun H, Deng M, Chen W, Liu M, Dai H, Wang C. Graft dysfunction and rejection of lung transplant, a review on diagnosis and management. *Clin Respir J* 2022;16(1):5–12.
- Madan R, Chansakul T, Goldberg HJ. Imaging in lung transplants: Checklist for the radiologist. *Indian J Radiol Imaging* 2014;24(4):318–26.
- Mondoni M, Rinaldo RF, Solidoro P, Di Marco F, Patrucco F, Pavesi S, et al. Interventional pulmonology techniques in lung transplantation. *Respiratory Medicine* 2023;211:107212.
- Mondoni M, Sferazza Papa GF, Sotgiu G, Carlucci P, Pellegrino GM, Centanni S. Haemoptysis: a frequent diagnostic challenge. *Eur Respir J* 2016;47(1):348–50.
- Larici AR, Franchi P, Occhipinti M, Contegiacomo A, del Ciello A, Calandriello L, et al. Diagnosis and management of hemoptysis. *Diagn Interv Radiol* 2014;20(4):299–309.
- Shao H, Wu J, Wu Q, Sun X, Li L, Xing Z, et al. Bronchial artery embolization for hemoptysis: a retrospective observational study of 344 patients. *Chin Med J (Engl)* 2015;128(1):58–62.
- Sadidi S, Roozafzai F, Nekooei S, Jarahi L, Khoroushi F. Predictors of 12-Month Recurrence of Hemoptysis after Bronchial Artery Embolization. *Arch Iran Med* 2025;28(2):100–6.
- Xu S, Guan LJ, Shi BQ, Tan YS, Zhang XJ. Recurrent Hemoptysis After Bronchial Artery Embolization: Prediction Using a Nomogram and Artificial Neural Network Model. *American Journal of Roentgenology* 2020;215(6):1490–8.
- Occhipinti M, Filippi AR, Walsh S, van Meerbeeck JP. Editorial: Imaging assessment of response to immunotherapy. *Front Oncol* 2022;12:1116315.
- Lambin P, Rios-Velazquez E, Leijenaar R, Carvalho S, Van Stiphout RGPM, Granton P, et al. Radiomics: Extracting more information from medical images using advanced feature analysis. *European Journal of Cancer* 2012;48(4):441–6.
- Lee G, Park H, Bak SH, Lee HY. Radiomics in Lung Cancer from Basic to Advanced: Current Status and Future Directions. *Korean J Radiol* 2020;21(2):159.
- Zhao X, Qiu X. Computed tomography radiomics-based prognosis prediction of patients with chronic obstructive pulmonary disease. *Journal of Radiation Research and Applied Sciences* 2024;17(4):101168.
- Depeursinge A, Chin AS, Leung AN, Terrone D, Bristow M, Rosen G, et al. Automated classification of usual interstitial pneumonia using regional volumetric texture analysis in high-resolution computed tomography. *Invest Radiol* 2015;50(4):261–7.
- Marchi G. Artificial intelligence for pleural effusion and pneumothorax detection on thoracic ultrasound: an educational viewpoint on promise, pitfalls, and path forward. *Breathe* 2026 [In Press].
- Cousin F, Louis T, Frères P, Guiot J, Occhipinti M, Bottari F, et al. Machine Learning Model Integrating CT

- Radiomics of the Lung to Predict Checkpoint Inhibitor Pneumonitis in Patients with Advanced Cancer. *Technol Cancer Res Treat* 2025;24:15330338251344004.
30. Marchi G, Fanni SC, Mercier M, Cefalo J, Salerni C, Ferioli M, et al. Artificial intelligence and radiomics in drug-induced interstitial lung disease. *ERJ Open Res* 2025;01150–2025.
 31. <https://ginasthma.org/reports/>
 32. <https://goldcopd.org/2026-gold-report/>
 33. Kim WD. Phenotype of Chronic Obstructive Pulmonary Disease Based on Computed Tomography-Defined Underlying Pathology. *Tuberc Respir Dis (Seoul)* 2022;85(4):302–12.
 34. Varricchi G, Poto R, Lommatzsch M, Brusselle G, Braido F, Virchow JC, et al. Biologics and airway remodeling in asthma: early, late, and potential preventive effects. *Allergy* 2025;80(2):408–22.
 35. Götschke J, Walter J, Leuschner G, Gerckens M, Götschke M, Mertsch P, et al. Mucus Plug Score Predicts Clinical and Pulmonary Function Response to Biologic Therapy in Patients With Severe Asthma. *The Journal of Allergy and Clinical Immunology: In Practice* 2025;13(5):1110–1122.e1.
 36. Benlala I, Dournes G, Girodet PO, Laurent F, Ben Hassen W, Baldacci F, et al. Bronchial wall T2w MRI signal as a new imaging biomarker of severe asthma. *Insights Imaging* 2025;16(1):71.
 37. Shah DJ, Esposito A, Pitaktong A, Sauthoff H. Thoracic ultrasound in interstitial lung disease. *Breathe (Sheff)* 2025;21(2):240170.
 38. Zheng S, Zhou Z, Du G, Chen Q, Chen S, Lin J, et al. The diagnostic utility of lung ultrasound in the assessment of interstitial lung disease associated with rheumatoid arthritis. *Arthritis Res Ther* 2025;27(1):159.
 39. Otaola M, Vasarmidi E, Ottaviani S, Gutierrez M, Dalpiaz MS, Gaser A, et al. Performance of Lung Ultrasound as a Screening Tool for Subclinical Rheumatoid Arthritis-Associated Interstitial Lung Disease. *CHEST* 2025;167(6):1687–95.
 40. Laursen CB, Clive A, Halifax R, Pietersen PI, Asciak R, Davidsen JR, et al. European Respiratory Society statement on thoracic ultrasound. *Eur Respir J* 2021;57(3):2001519.
 41. Mondoni M, Saderi L, Trogu F, Terraneo S, Carlucci P, Ghelma F, et al. Medical thoracoscopy treatment for pleural infections: a systematic review and meta-analysis. *BMC Pulm Med* 2021;21(1):127.
 42. Lovato JB, Aujayeb A, Duysinx B, Astoul P. The Evolving Role of Medical Thoracoscopy for the Management of Malignant Pleural Effusion. *Curr Oncol* 2025;32(12):670.
 43. Lee HJ, Akulian JA, Argento AC, Batra H, Lamb C, Mullon J, et al. Interventional Pulmonary Fellowship Training: End of the Beginning. *ATS Scholar* 2023;4(4):405–12.
 44. Marchi G, Mercier M, Cefalo J, Salerni C, Ferioli M, Candoli P, et al. Advanced imaging techniques and artificial intelligence in pleural diseases: a narrative review. *Eur Respir Rev* 2025;34(176):240263.
 45. Marchi G. The road less travelled: thoracic ultrasound, advanced imaging and artificial intelligence for early diagnosis of non-expandable lung in malignant pleural effusion. *Breathe* 2025;21(3):250179.
 46. Marchi G. Artificial Intelligence in Interventional Pulmonology: Promise versus Proof. *Respiration* 2025;1–2.
 47. Marchi G, Gabbriellini L, Gherardi M, Serradori M, Baglivo F, Fanni SC, et al. Artificial Intelligence-Based Automated Analysis for Pleural Effusion Detection on Thoracic Ultrasound: A Systematic Review. *Diagnostics* 2026;16(1):147.
 48. Marchi G, Cucchiara F, Gregori A, Biondi G, Guglielmi G, Serradori M, et al. Thoracic Ultrasound for Pre-Procedural Dynamic Assessment of Non-Expandable Lung: A Non-Invasive, Real-Time and Multifaceted Diagnostic Tool. *JCM* 2025;14(6):2062.
 49. Marchi G. Exploring pleural effusion characterisation with quantitative thoracic ultrasound imaging: a viewpoint on the investigational role of pixel-based echogenicity analysis in transudate and exudate differentiation. *Breathe* 2025;21(4):250282.
 50. Marchi G, Chaabouni M, Bakiri K, et al. ERS Congress 2025: highlights from the Clinical Techniques, Imaging and Endoscopy Assembly. *ERJ Open Res* 2026;12:01564–2025.
 51. Bedawi EO, Talwar A, Hassan M, McCracken DJ, Asciak R, Mercer RM, et al. Intercostal vessel screening prior to pleural interventions by the respiratory physician: a prospective study of real world practice. *Eur Respir J* 2020;55(4):1902245.
 52. Marchi G, Cinquini S, Tannura F, Guglielmi G, Gelli R, Pantano L, et al. Intercostal Artery Screening with Color Doppler Thoracic Ultrasound in Pleural Procedures: A Potential Yet Underexplored Imaging Modality for Minimizing Iatrogenic Bleeding Risk in Interventional Pulmonology. *JCM* 2025;14(17):6326.
 53. Deng M, Xia Y, Ye X, Ma J, Zhao S, Zhang Q, et al. Ultrasonic elastography-guided pleural biopsy versus traditional thoracic ultrasound-guided pleural biopsy for the diagnosis of pleural effusion: a multicentre, randomised trial. *Eur Respir J* 2025;66(6):2501062.
 54. Safai Zadeh E, Weide J, Dietrich CF, Trenker C, Koczulla AR, Görg C. Diagnostic Accuracy of B-Mode- and Contrast-Enhanced Ultrasound in Differentiating Malignant from Benign Pleural Effusions. *Diagnostics (Basel)* 2021;11(7):1293.
 55. Baribeau Y, Sharkey A, Chaudhary O, Krumm S, Fatima H, Mahmood F, et al. Handheld Point-of-Care Ultrasound Probes: The New Generation of POCUS. *J Cardiothorac Vasc Anesth* 2020;34(11):3139–45.
 56. Causio FA, DE Angelis L, Diedenhofen G, Talio A, Baglivo F, Workshop Participants. Perspectives on AI use in medicine: views of the Italian Society of Artificial Intelligence in Medicine. *J Prev Med Hyg* 2024;65(2):E285–9.
 57. Ahmed MI, Spooner B, Isherwood J, Lane M, Orrock E, Dennison A. A Systematic Review of the Barriers to the Implementation of Artificial Intelligence in Healthcare. *Cureus* 2023;15(10):e46454.
 58. Baloescu C, Bailitz J, Cheema B, Agarwala R, Jankowski M, Eke O, et al. Artificial Intelligence-Guided Lung Ultrasound by Nonexperts. *JAMA Cardiol* 2025;10(3):245.

59. Howell L, Ingram N, Lapham RC, Morrell A, McLaughlan JR. Deep learning for real-time multi-class segmentation of artefacts in lung ultrasound. Vol. 140, Ultrasonics. Elsevier B.V.; 2024.
60. Ibrahim M, Khalil YA, Amirrajab S, Sun C, Breeuwer M, Pluim J, et al. Generative AI for synthetic data across multiple medical modalities: A systematic review of recent developments and challenges. *Computers in Biology and Medicine* 2025;189:109834.
61. Abgrall G, Holder AL, Chelly Dagdia Z, Zeitouni K, Monnet X. Should AI models be explainable to clinicians? *Crit Care* 2024;28(1):301.
62. Marchi, G.; Gambini, G.; Guglielmi, G.; Pistelli, F.; Carrozzi, L. Valutazione comparativa di modelli linguistici di grandi dimensioni per il supporto all'educazione sanitaria del paziente con BPCO: Uno studio pneumologico internazionale delle risposte generate da ChatGPT-4, Claude 3.5 Sonnet e Gemini 1.5 Advanced. *Recent. Progress. Med.* 2025, 116, 571–572.
63. Marchi G. Decoding the “black-box”: explainable artificial intelligence towards trustworthy advancement in respiratory medicine. *Breathe* 2026 [In Press].
64. Ferioli M, Romagnoli M, Candoli P. Editorial: Advances in bronchoscopic techniques for the diagnosis of lung cancer. *Front Oncol* 2024;14:1428006.
65. Carvalho C, Van Heumen S, Funke F, Heuvelmans MA, Serino M, Frille A, et al. The role of interventional pulmonology in management of pulmonary nodules during lung cancer screening. *Breathe* 2025;21(4):240256.
66. Gorini, G.; Puliti, D.; Picozzi, G.; Giovannoli, J.; Veronesi, G.; Pistelli, F.; Senore, C.; Tessa, C.; Cavigli, E.; Bisanzi, S.; et al. CCM-ITALUNG2 pilot on lung cancer screening in Italy: Recruitment, integration with smoking cessation and baseline results. *Radiol. Medica* 2025.
67. Brock JM, Dittrich AS, Kontogianni K, Heussel CP, Klotz LV, Winter H, et al. First European Experience of Shape-Sensing Robotic-Assisted Bronchoscopy: Learning Curve Analysis. *Respiration* 2025;104(10):736–49.
68. Chang ATC, Chan JWY, Siu ICH, Liu W, Lau RWH, Ng CSH. Robotic-assisted bronchoscopy-advancing lung cancer management. *Front Surg* 2025;12:1566902.
69. Corbetta L, Arru LB, Mereu C, Pasini V, Patelli M. Competence and training in interventional pulmonology. *Panminerva Med* 2019;61(3).
70. Mondoni M, Wahidi MM, Sotgiu G. Combination of cryobiopsy with EBUS-TBNA—Might rapid on-site evaluation successfully drive patient selection? *Pulmonology* 2024;30(5):416–8.
71. Mondoni M, Sotgiu G. Optimizing the endoscopic diagnosis of mediastinal lymphadenopathy: a glimpse on cryobiopsy. *BMC Pulm Med* 2022;22(1):355.
72. Poletti V, Tomassetti S, Ravaglia C. Time to Trust Transbronchial Cryobiopsy in Identification of Usual Interstitial Pneumonia Pattern? *Am J Respir Crit Care Med* 2021;203(10):1218–20.
73. Roselló SP, Alonso-Fernández A, Anieto MB, Valades AF, Bellvert CG, Cosío BG, et al. Diagnostic performance and safety of endobronchial ultrasound-guided transbronchial cryobiopsies in the diagnosis of mediastinal lesions. *Respiratory Medicine* 2025;247:108294.
74. Misra S, Bandyopadhyay A, Patra A, Mitra R, Sengupta A, Kundu S. A single-centre, randomised trial to compare diagnostic yield and safety between endobronchial cryobiopsy and endobronchial forceps biopsy procedure in patients with endobronchial lesions. *Lung India* 2025;42(3):204–10.
75. Luppi F, Manfredi A, Faverio P, Franco G, Salvarani C, Bendstrup E, et al. Treatment of acute exacerbation in interstitial lung disease secondary to autoimmune rheumatic diseases: More questions than answers. *Autoimmunity Reviews* 2024;23(12):103668.
76. Luppi F, Kalluri M, Faverio P, Kreuter M, Ferrara G. Idiopathic pulmonary fibrosis beyond the lung: understanding disease mechanisms to improve diagnosis and management. *Respir Res* 2021;22(1):109.
77. Fahim A. Idiopathic pulmonary fibrosis—A challenging disease with new horizons and changing therapeutic landscape. *Clinical Respiratory J* 2021;15(4):369–73.
78. Qiu Y, Ye W. Therapeutic efficacy of pirfenidone and nintedanib in pulmonary fibrosis; a systematic review and meta-analysis. *Ann Thorac Med* 2025;20(3):145–52.
79. Maher TM, Assassi S, Azuma A, Cottin V, Hoffmann-Vold AM, Kreuter M, et al. Nerandomilast in Patients with Progressive Pulmonary Fibrosis. *N Engl J Med* 2025;392(22):2203–14.

Received for publication: 14 January 2026 Accepted for publication: 3 February 2026

This work is licensed under a Creative Commons Attribution-NonCommercial 4.0 International License (CC BY-NC 4.0).

©Copyright: the Author(s), 2026

Licensee Mattioli 1885, Italy

Multidisciplinary Respiratory Medicine 2026; 21: 1086

doi: 10.5826/mrm.2026.1086

Publisher's note: all claims expressed in this article are solely those of the authors and do not necessarily represent those of their affiliated organizations, or those of the publisher, the editors and the reviewers. Any product that may be evaluated in this article or claim that may be made by its manufacturer is not guaranteed or endorsed by the publisher.